

# Acute Angle Closure for Emergency Medicine Physicians

Niamh Collins

Glaucoma Fellow RVEEH Melbourne

14/03/2017

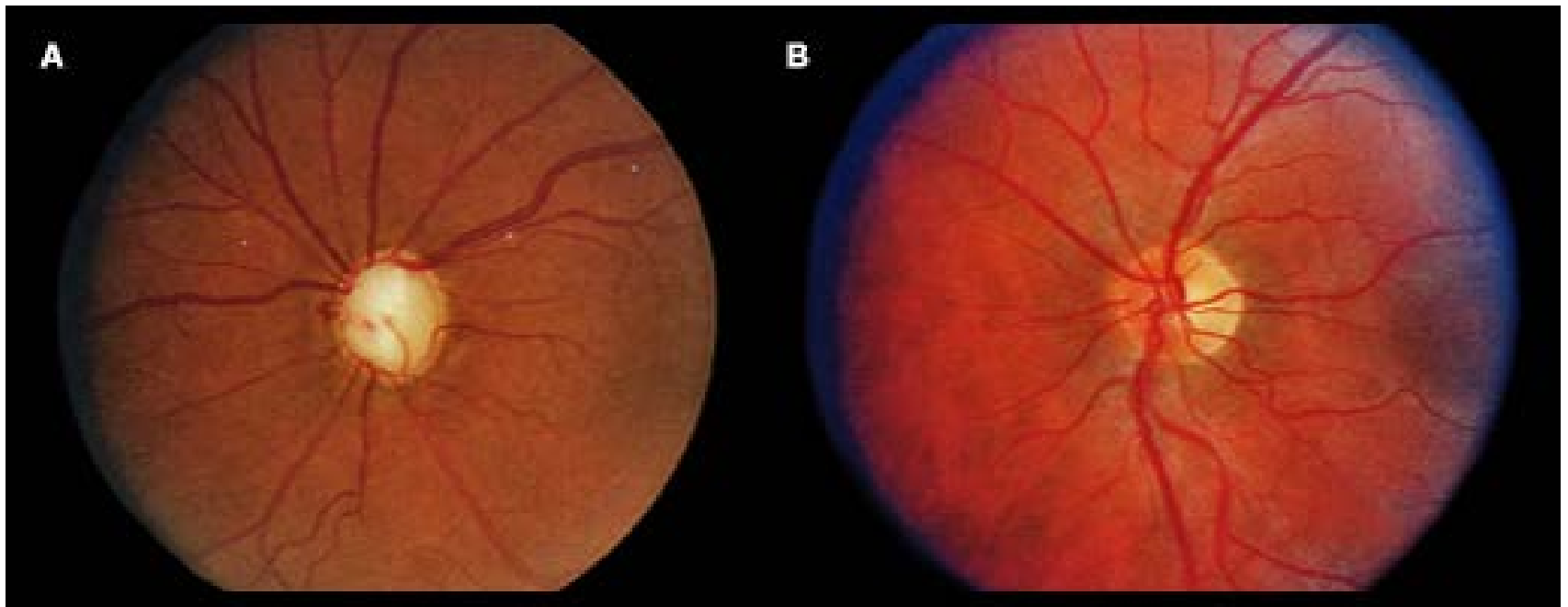
# Some definitions to avoid confusion!

“Glaucoma” is a group of eye diseases traditionally characterized by elevated intraocular pressure (IOP)

... However, glaucoma is more accurately defined as an **optic neuropathy** and **may not always be associated with elevated IOP**

# Some definitions to avoid confusion!

Glaucoma is defined as  
an optic neuropathy involving  
a characteristic atrophy of the optic nerve head,  
often accompanied by typical visual field defects

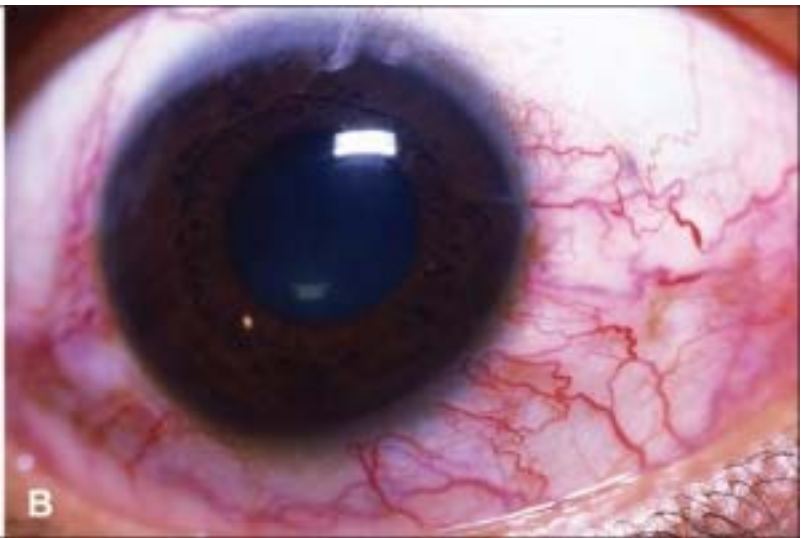
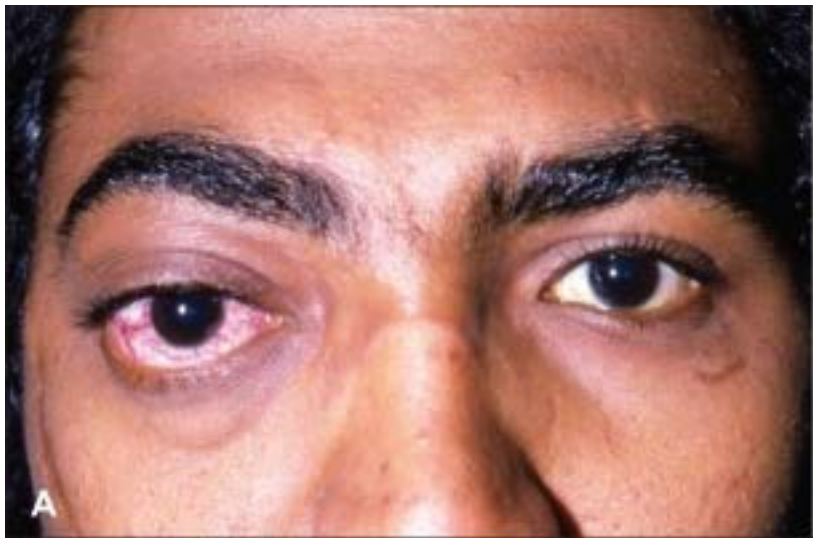
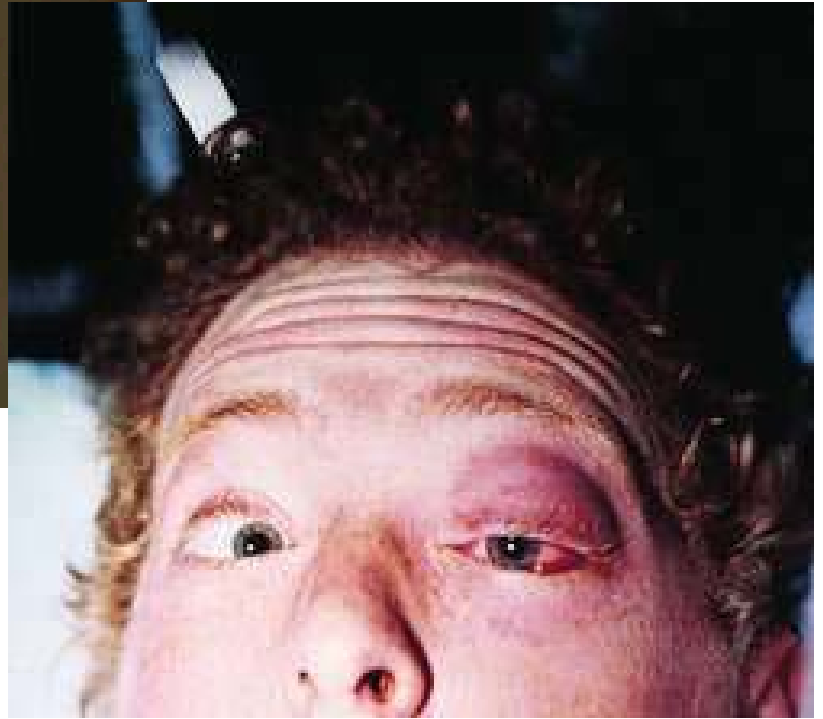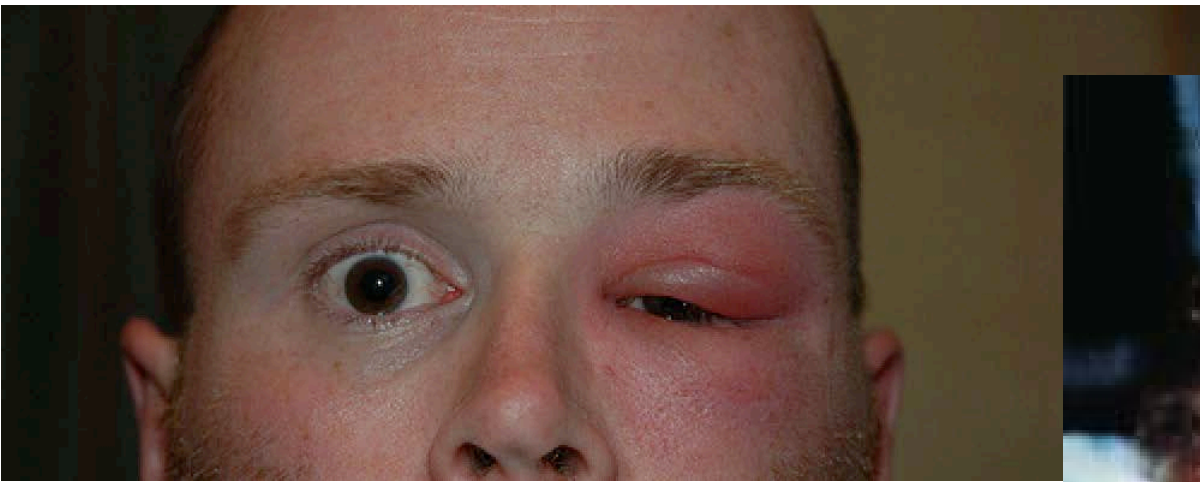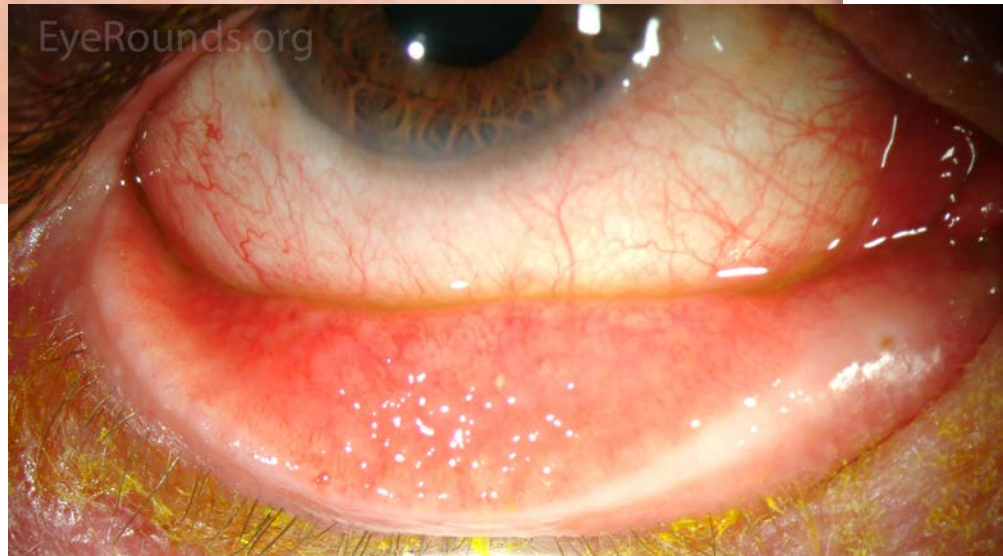
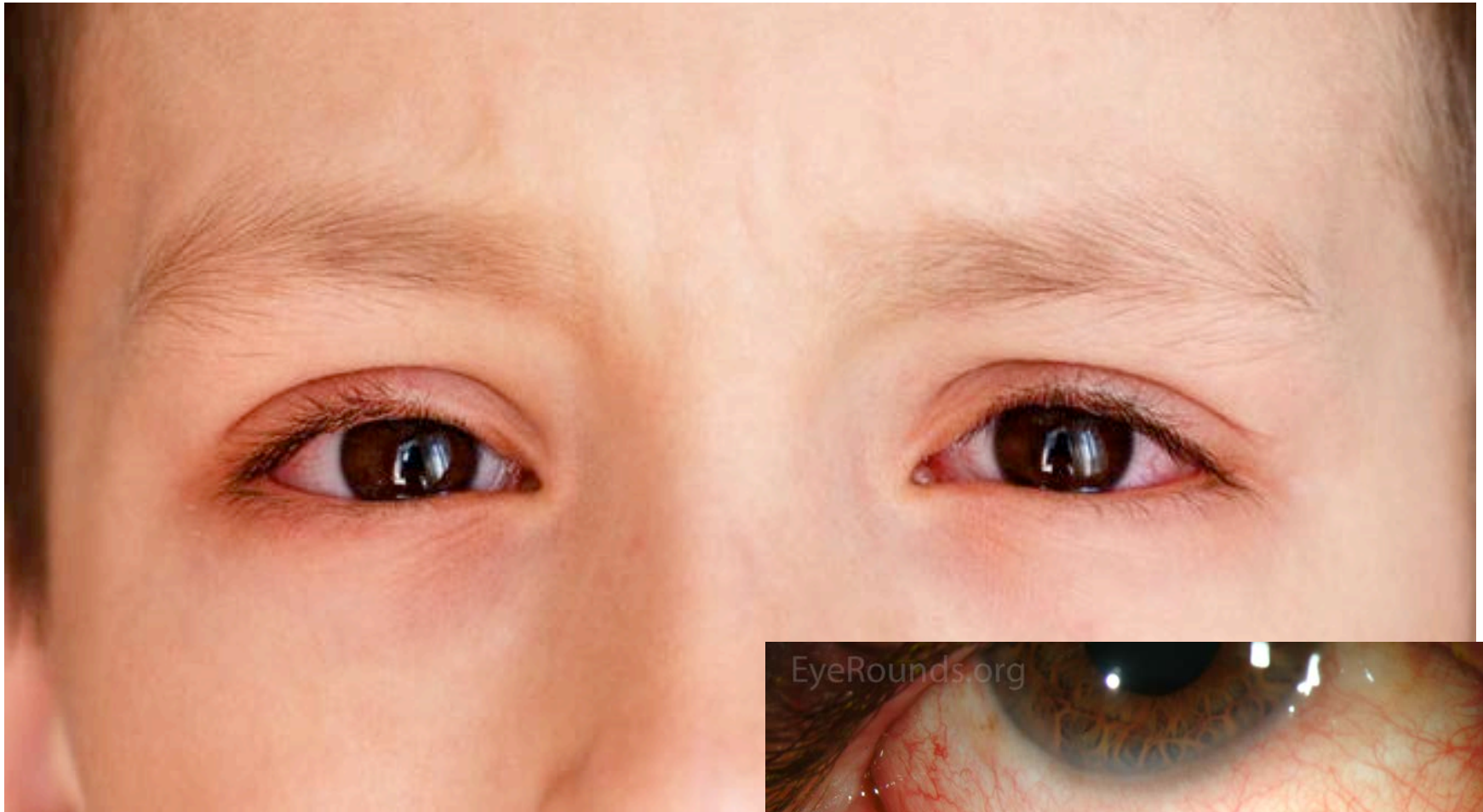# Some definitions to avoid confusion!

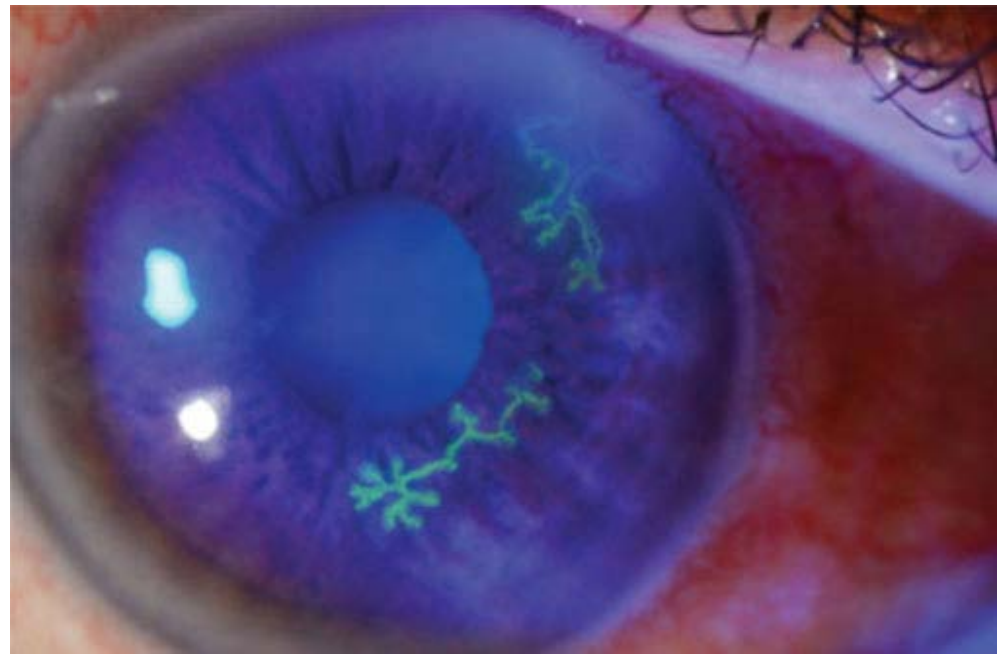
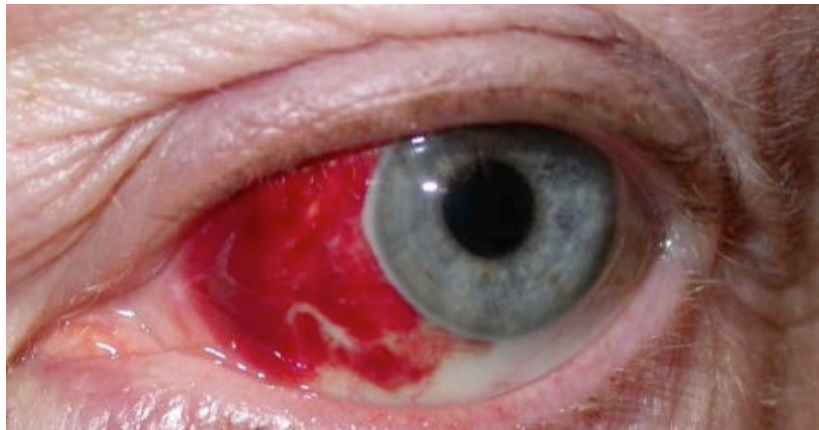
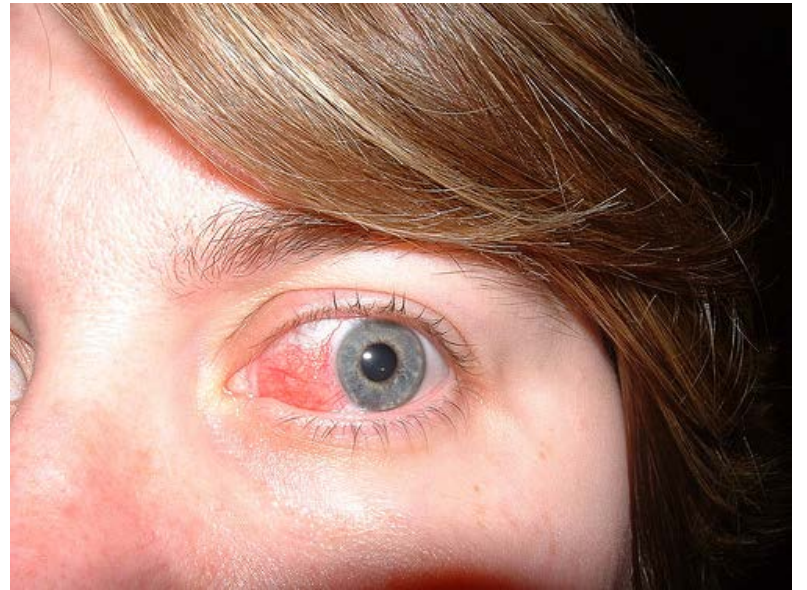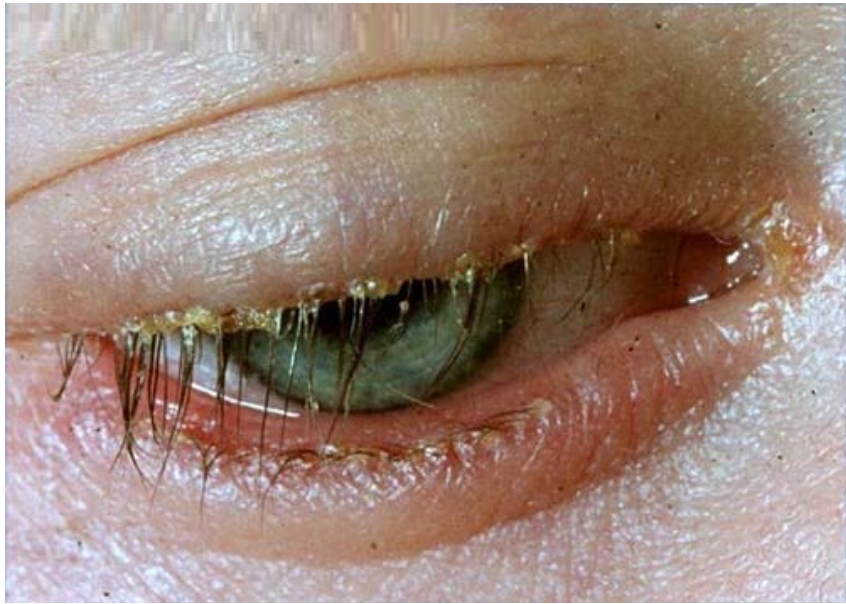- **Acute** angle closure
  - closed anterior chamber drainage angle with high IOP and acute symptoms and signs of high IOP (pain, nausea, redness, corneal oedema etc.)
- Angle closure **glaucoma**
  - patient has a history of angle closure (acute or chronic) AND **glaucomatous optic neuropathy** (i.e. angle closure + disc changes and visual field loss)

# The Red Eye

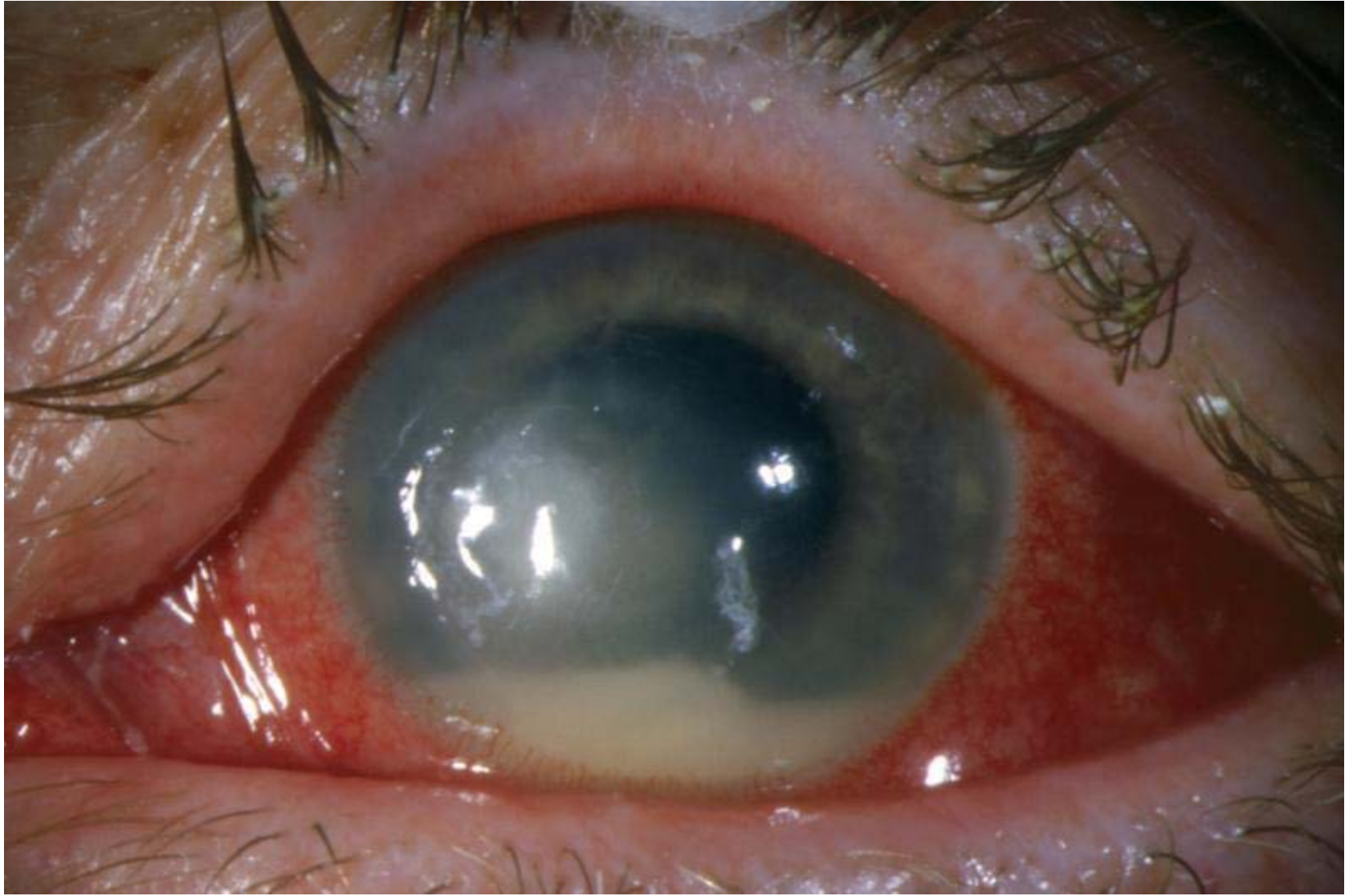
- Simple differential:
  - Extra-ocular (orbit)
    - E.g. pre-septal / orbital cellulitis, CST, CCF
  - External eye disease (eyelids, conj., sclera, cornea)
    - E.g. blepharitis, conjunctivitis, episcleritis, keratitis
  - Internal eye disease (AC, iris & ciliary body)
    - E.g. iritis / uveitis, **acute angle closure**

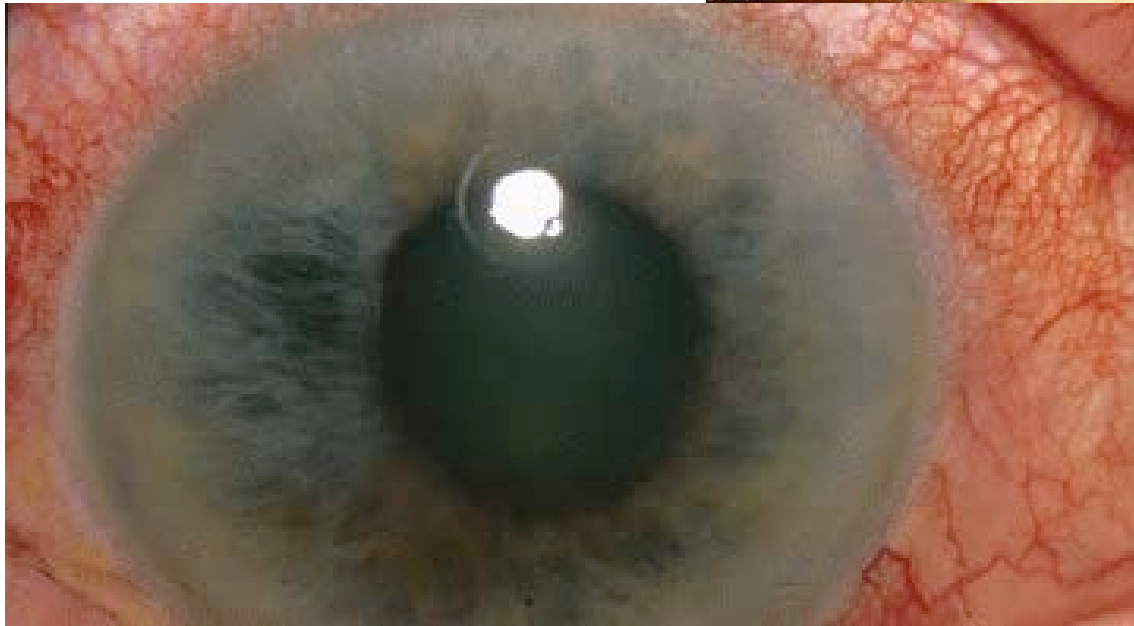
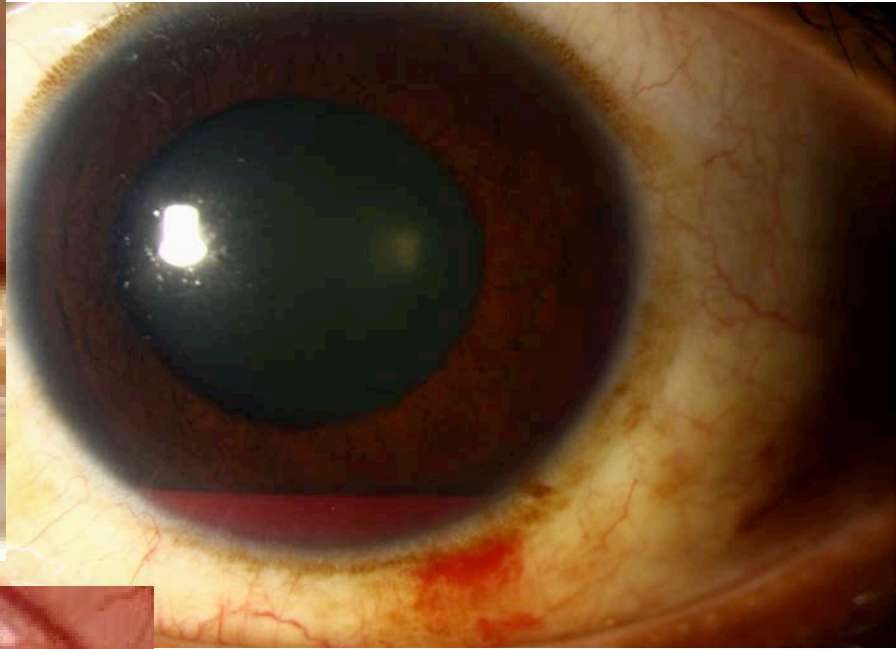
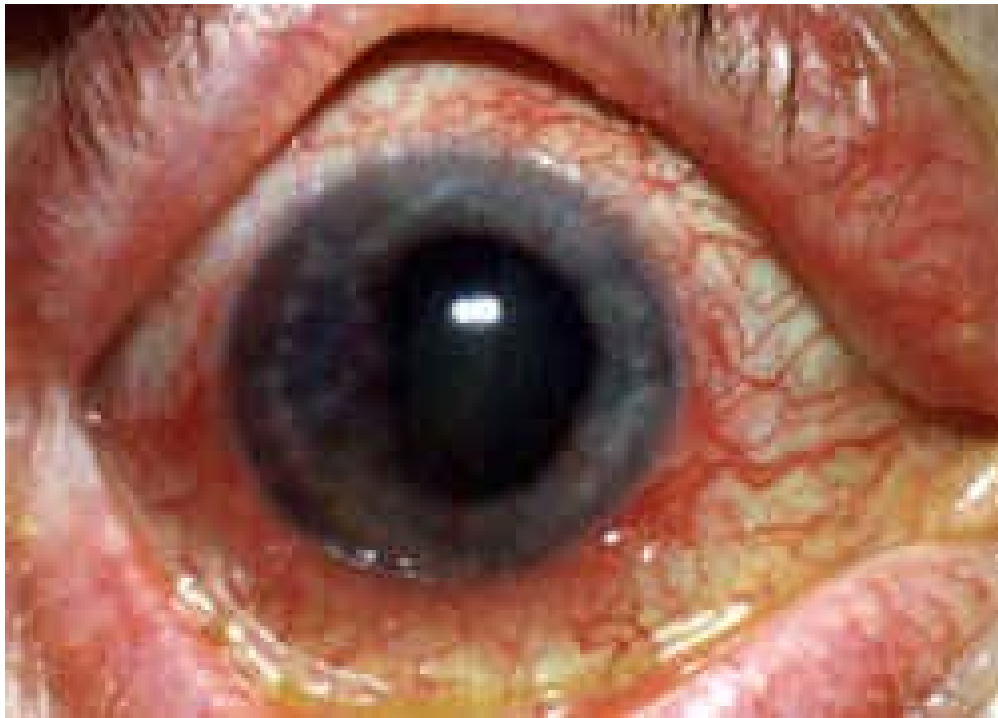






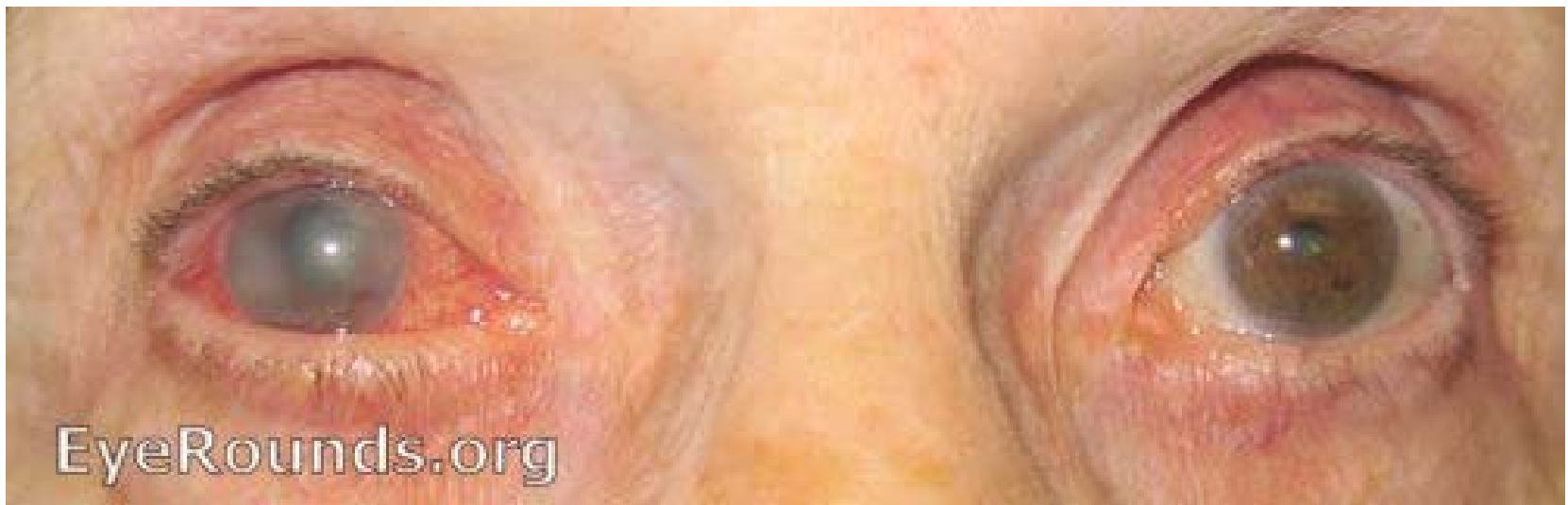




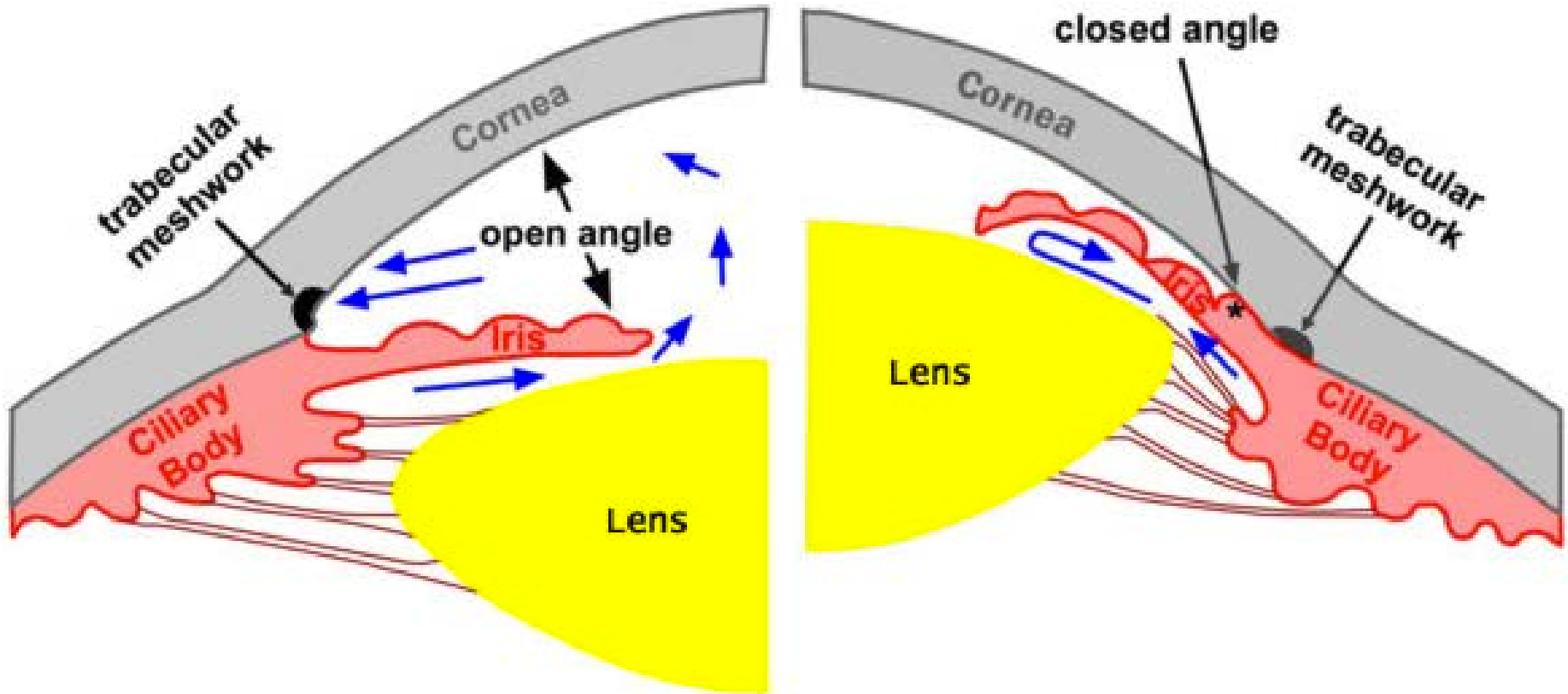
# True or False: features suggestive of an internal cause of painful red eye?

- Severe eye pain unrelieved by topical anesthetics
- Impaired vision
- Eye discharge is common (watery, mucoid or purulent)
- Poorly reactive pupils
- Abnormal slit lamp examination +/- abnormal IOP
- Pain sensation is usually itching, gritty, scratching, or burning
- Pain is significantly improved by topical anesthetics
- Blepharospasm
- Visual acuity normal or near-normal (some blurriness)
- Preauricular lymphadenopathy



- Patient awoke with severe pain in RE, headache, decreased vision, nausea
- Right eye was very firm with a pressure of 70+ mmHg
- Refractive error was +1.50 to +2.00 sphere in each eye
- Examination of LE showed a narrow AC by comparing width between slit beams
  - Von Herrick Test showed a narrow angle in the left eye [Distance between slit beams should be at least 1/2 of the corneal thickness (~250 microns)]
- Gonioscopy demonstrated a closed angle in LE also

# What is “Angle Closure”?

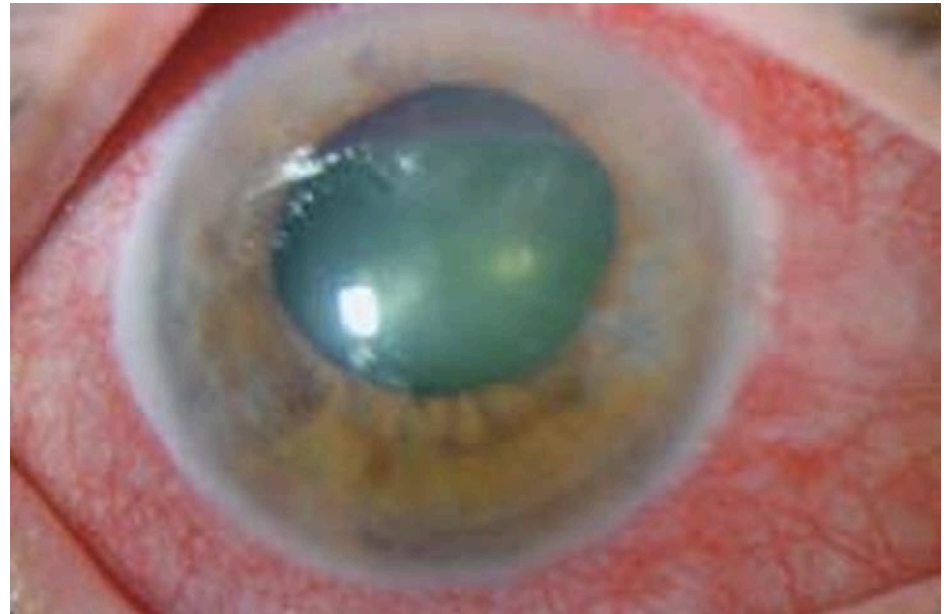

Acute angle closure (AAC) is the acute elevation of IOP due to diminished outflow of aqueous humor through the anterior chamber of the eye into the peripherally located canal of Schlemm

- It occurs in 1 in 1000 Caucasians and as frequently as 1 in 100 people of Asian origin
- Medical or surgical therapy is directed at widening the angle and preventing further angle closure

# Classic History & Exam Features

- Presence of risk factors (eg, hyperopia, thick cataractous lens)
- Halos around lights
- Aching eye or brow pain (not relieved by topical anaesthesia)
- Headache
- Nausea, vomiting
  
- Reduced acuity
- Eye redness
- Closed angle on gonioscopy
- Extremely high IOP
- Corneal edema
- Engorged conjunctival vessels
- Fixed dilated pupil
- +/- Iris bombe



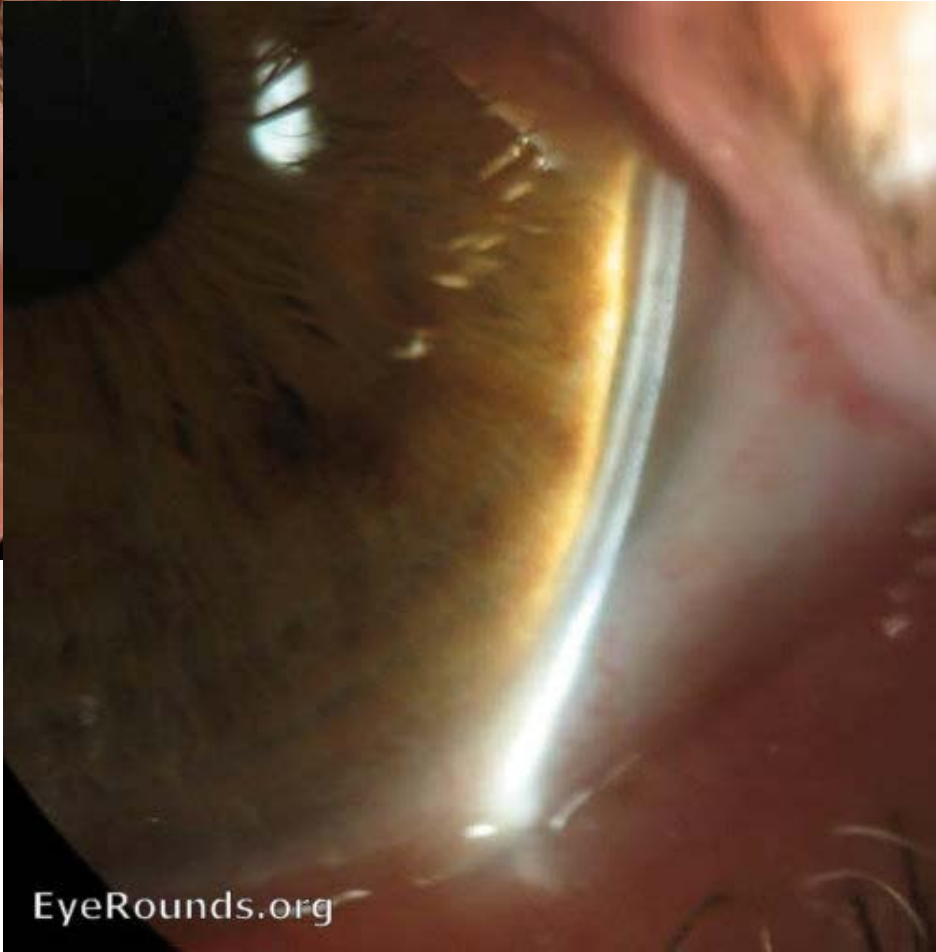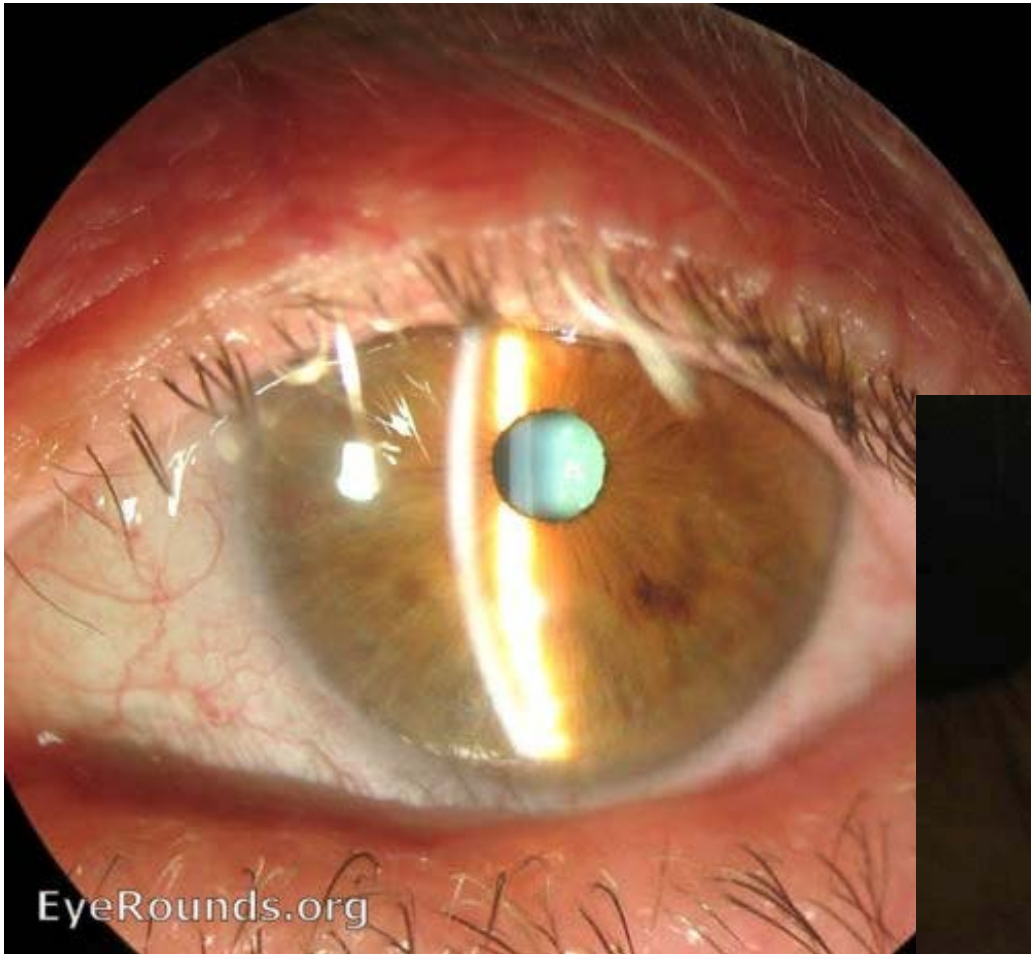
# Precipitating Factors for AAC

- Dim illumination
- Emotional stress
- Mydriasis (warning labels for “glaucoma”)
  - Anticholinergics, antihistamine, antidepressant, adrenergics, CNS stimulants, bronchodilators
  - Usually happens as pupil is constricting slowly *after* dilation



# AAO criteria for AAC diagnosis

- At least 2 of the following symptoms:
  - ocular pain
  - history of intermittent visual blurring which may include the complaint of seeing halos
  - nausea or vomiting
- At least 3 of the following signs:
  - IOP greater than 21 mm Hg
  - corneal edema
  - conjunctival injection
  - mid-dilated minimally reactive pupil
  - shallow anterior chamber



# Van Herick Grading

## PRIMARY ANGLE-CLOSURE GLAUCOMA

**VAN HERICK METHOD OF SLIT-LAMP GRADING**

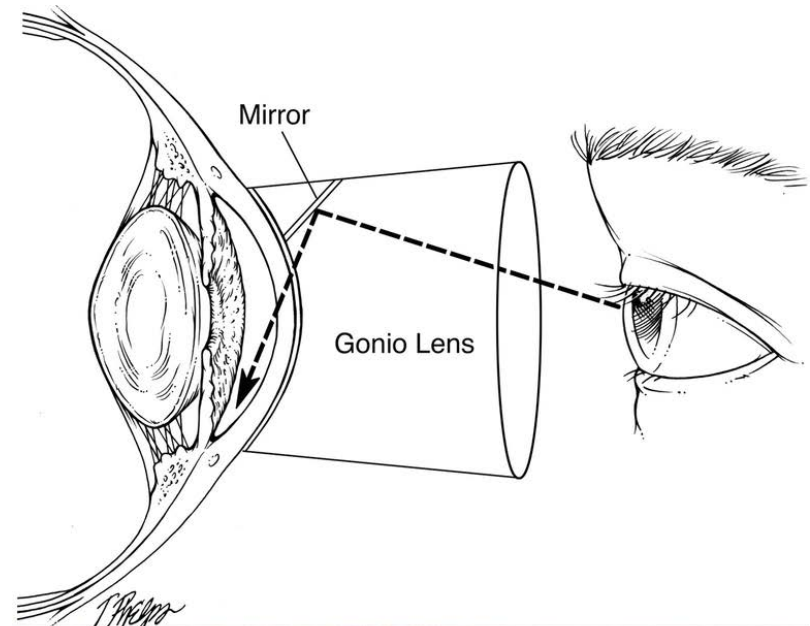
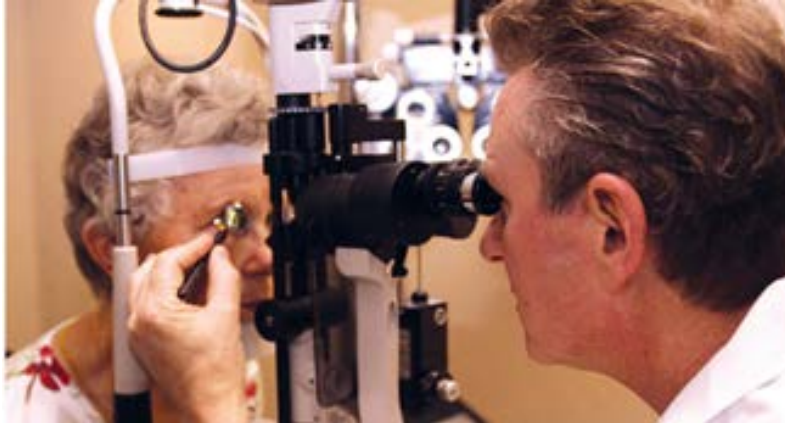**GRADES:**

- Grade 4 (WIDE OPEN ANGLE)**
  - PACD =  $3/4$  to 1 CT
- Grade 3 (MILD NARROW)**
  - PACD =  $1/4$  to  $1/2$  CT
- Grade 2 (MODERATE NARROW)**
  - PACD =  $1/4$  CT
- Grade 1 (EXTREMELY NARROW)**
  - PACD <  $1/4$  CT
- Grade 0 (CLOSED ANGLE)**
  - PACD Nil

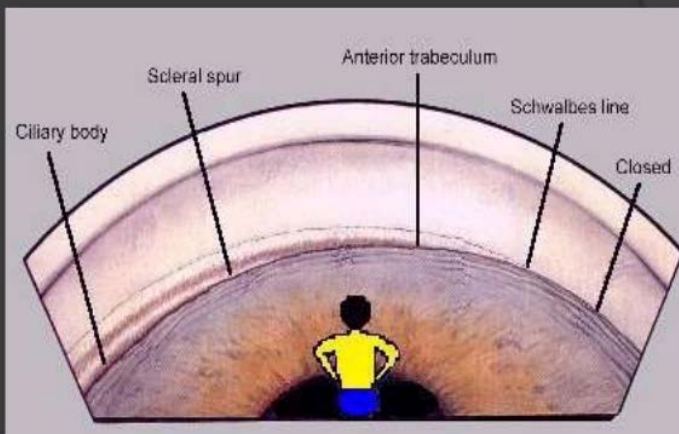
**A – Grade IV**  
**B – Grade III**  
**C – Grade II**  
**D – Grade I**  
**E – Grade 0**

**Slit lamp**      **Anatomic**

# What is Gonioscopy?



## Diagnosis



# OBLIQUE FLASHLIGHT TEST

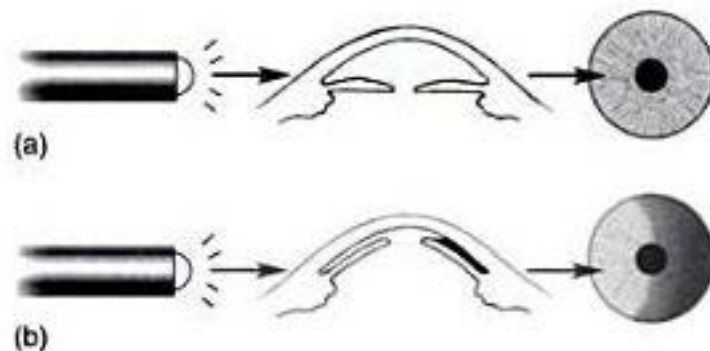
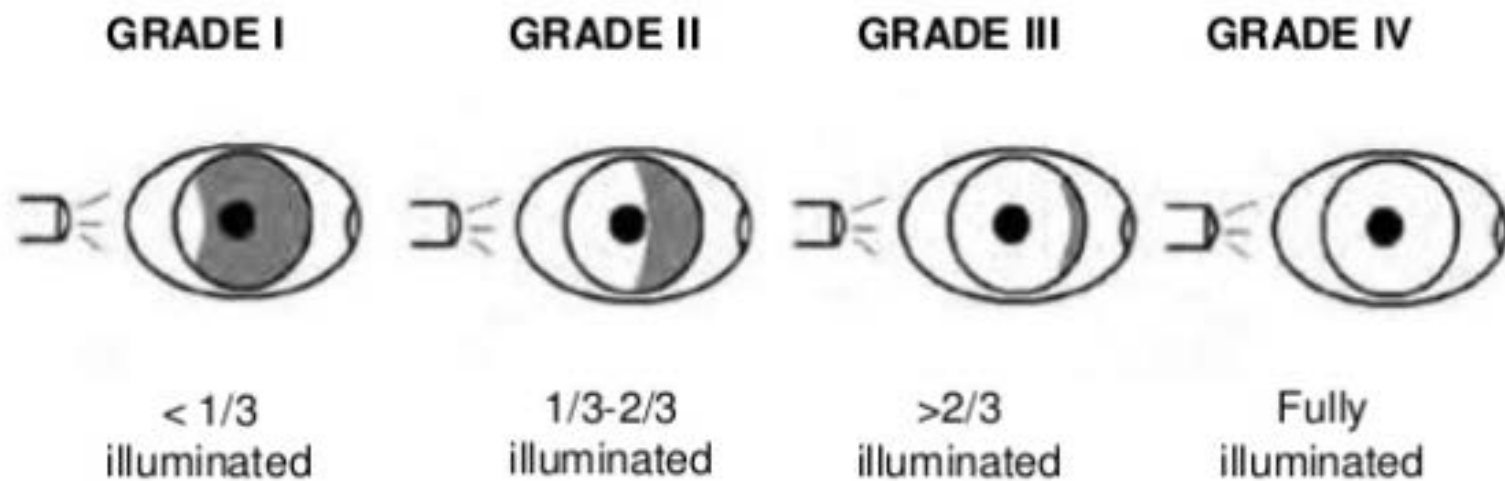


Figure 21.7  
Oblique flashlight test: (a) normal and (b) shallow anterior chamber.



Diagnosis made, what next?

# Initial Medical Management of Acute Angle Closure (1)

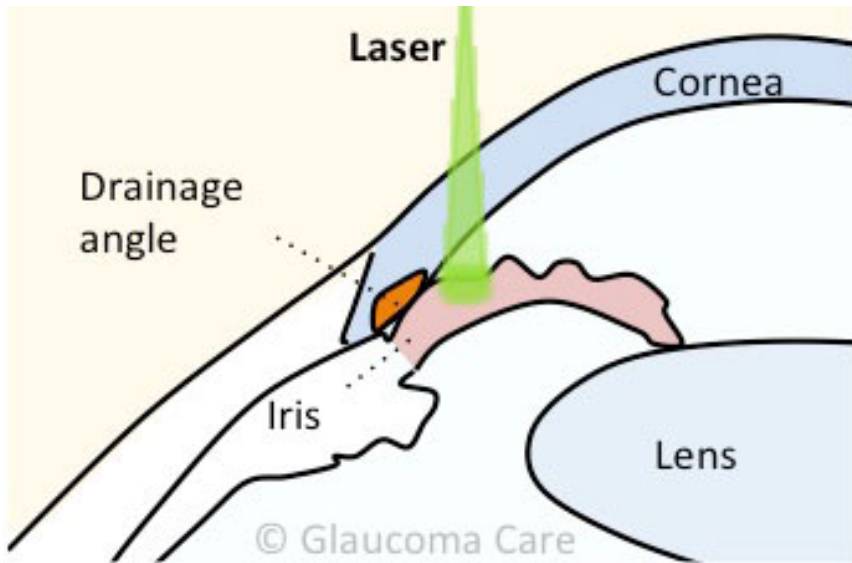
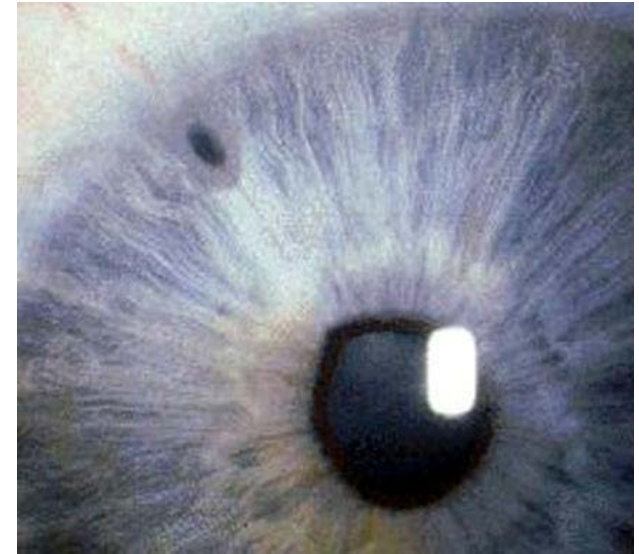
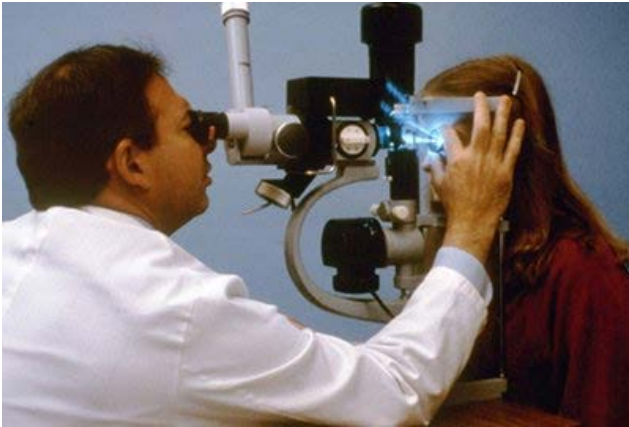- Immediate goal of treatment is to relieve acute symptoms and decrease IOP, usually achieved with medical therapy
- Oral or topical carbonic anhydrase inhibitors, topical beta-blockers, and topical alpha-2 adrenergic agonists lower IOP through suppression of aqueous humor production
  - **Oral CAI** reduce IOP by 30 – 50%
    - Acetazolamide 500mg PO: onset 30 – 60min; peak 4 hrs; duration 4 – 6hrs
    - **Acetazolamide 500mg IV**: onset 1min; peak 15min; duration 4hrs
    - (Topical CAI reduce IOP by 15 – 20%)
  - **Beta-blockers** reduce IOP by 20 - 30% within 1hr
  - **Alpha-agonists** reduce IOP by 26% within 2hrs
- CAIs, topical beta-blockers, alpha-2 adrenergic agents used typically in combination

# Initial Medical Management of Acute Angle Closure (2)

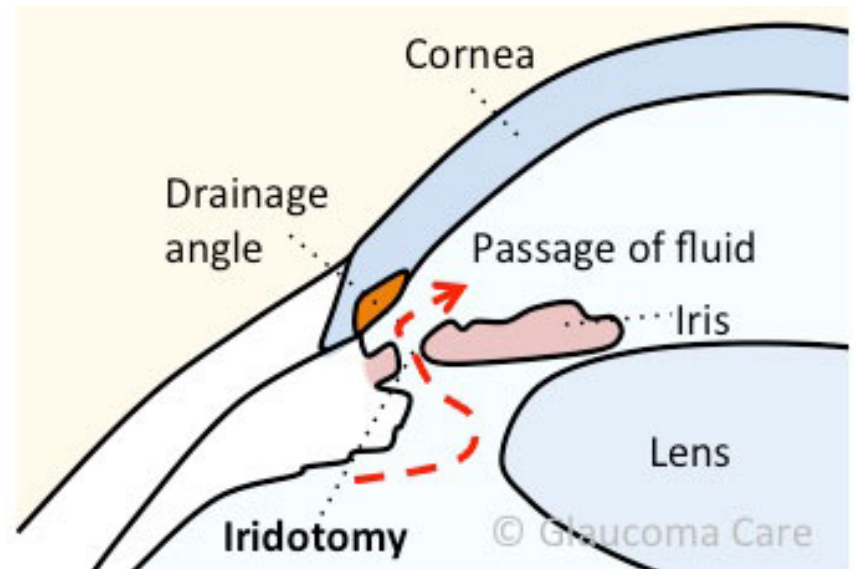
- Where AAC is thought to be secondary to pupillary block, cholinergic agents (**pilocarpine**) should be started after IOP decreases to  $< 40\text{mmHg}$
- If these treatments are unsuccessful, use hyperosmotic agents (sometimes also used initially when IOP very high ( $> 50\text{mmHg}$ ))
  - Glycerine, 1-2 g/kg/dose orally, repeat every 5 hours when required
  - **Mannitol, 1.5 to 2 g/kg/dose intravenously over 30 minutes**
- Following resolution of acute attack, definitive surgical treatment (LPI) performed within 24 - 48 hours to achieve a persistently open angle
  - (when corneal edema resolves – cornea usually too hazy to laser during acute attack)
  - may consider lens extraction after acute attack resolved



Medication Class	Medication	Pharmacology	Adverse Effects/Cautions
Beta Blockers	Timolol 0.5%	Decrease production of aqueous humor	Systematically absorbed/caution in asthma/COPD
Alpha 2 Agonists	Brimonidine 0.15%	Decrease production of aqueous humor and increase outflow	
Carbonic Anhydrase Inhibitors	Acetazolamide (Diamox) 500 mg IV or PO	Decrease production of aqueous humor	Sulfa drug; Use caution in Sulfa allergic patients; Avoid in patients with Sickle cell disease (increased sickling)
Prostaglandin Analogs	Latanoprost 0.005%	Increase aqueous humor outflow	Browning of the iris
Muscarinic Agonists	Pilocarpine 1-2%	Increase aqueous humor outflow	Ineffective at high IOP
Topical Steroids	Prednisolone 1%	Decrease inflammation and synechiae formation	Use in conjunction with ophthalmology
Desiccating Agents/Hyperosmotic Agents	Mannitol 1-2g/kg IV	Draw fluid out of the vitreous humor by osmotic pressure	Caution with use in patients with intravascular volume depletion



Laser iridotomy



Angle opened

- How to perform a Laser Iridotomy
- <https://www.youtube.com/watch?v=2KTpudybmFU>

# Aetiology

- Angle closure can be primary, secondary to another eye disease, or drug induced.
  - Eye diseases that can cause angle closure:
    - thick cataractous lens (phacomorphic glaucoma); ectopic lens (eg, in settings of trauma, as well as Marfan's or Weill-Marchesani syndrome); neovascularization of the angle secondary to diabetic retinopathy or ocular ischemia; and tumors
  - Sulfa-containing drugs can cause angle closure by causing supraciliary body effusions
    - This form of angle closure has a distinctly different etiology and is not treated in the same fashion as PAC. It is unresponsive to laser PI and is treated with topical steroids and discontinuation of the causative drug, as well as topical and systemic IOP lowering drugs.
    - Topiramate, sulfonamides, phenothiazides

# Pathophysiology

- Angle closure occurs when the peripheral iris is in contact with the trabecular meshwork (TM), either intermittently (appositional closure) or permanently (synechial closure) – causing a relative seal
- Specific mechanisms leading to angle closure can be divided into 2 categories:
  - Mechanisms that push the iris from behind
    - The most common reason is relative pupillary block, but other reasons include plateau iris syndrome, enlarged or anteriorly displaced lens, and malignant glaucoma.
  - Mechanisms that pull the iris into contact with the TM
    - E.g. contraction of inflammatory membrane as in uveitis, fibrovascular tissue as in iris neovascularization, or corneal endothelium as in iridocorneal endothelial syndrome.

- Chronic intermittent friction between the iris and the TM can lead to progressive dysfunction of the TM. With time, adhesions (synechiae) form between the iris and parts of the TM.
- Eventually the TM is so dysfunctional or obstructed that aqueous outflow from the eye is impaired and IOP rises.
- Prolonged elevation of IOP leads anatomically to glaucomatous changes in the optic nerve head and loss of optic nerve axons and functionally to progressive loss of the visual field.
- If untreated this process may progress to complete blindness.
- Angle closure is usually chronic and progressive, but uncommonly it manifests as an acute attack of complete closure with severe symptoms.

# Key Points

- Consider AAC in all patients presenting with **headache and visual changes, especially if associated with nausea and vomiting**
- AAC occurs more frequently in **females and those of Asian descent**
- **Early and effective therapy is vital in reducing optic nerve ischemia and vision loss.** Time is optic nerve
- Be aware of the patient's **comorbidities and allergies before treating** (i.e. be aware of the risks of topical  $\beta$  blockers in COPD/asthma, sulfa allergy with acetazolamide use)
- **There is no emergent treatment that an ophthalmologist can offer that an emergency physician cannot. Definitive treatment is with LPI, however this is frequently delayed until corneal clearing occurs.** Thus topical and IV agents are paramount in early treatment of AAC

# A bit of history

- Before 1850, poor vision with a normal eye appearance, as occurs in primary open-angle glaucoma, was termed amaurosis, gutta serena, or black cataract. Few observers noted palpable hardness of the eye in amaurosis.
- On the other hand, angle-closure glaucoma can produce a green or gray pupil, and therefore was called, variously, glaucoma (derived from the Greek for glaucous, a nonspecific term connoting blue, green, or light gray) and viriditate oculi.
- Angle closure, with palpable hardness of the eye, mydriasis, and anterior prominence of the lens, was described in greater detail in the 18th and 19th centuries.
- The introduction of the ophthalmoscope in 1850 permitted the visualization of the excavated optic neuropathy in eyes with a normal or with a dilated greenish-gray pupil.
- Physicians developed a better appreciation of the role of intraocular pressure in both conditions, which became subsumed under the rubric “glaucoma”.